

VOLUME 115 • NUMBER 5 • APRIL 15, 2005



PRS
Advance Online
Articles Now Available
www.plasreconsurg.org

Plastic and Reconstructive Surgery®

Journal of the American Society of Plastic Surgeons

Official Organ of the American Association of Plastic Surgeons

Official Organ of the American Society for Aesthetic Plastic Surgery, Inc.

Official Organ of the American Society of Maxillofacial Surgeons



LIPPINCOTT
WILLIAMS & WILKINS

Plastic and Reconstructive Surgery®

EDITORIAL BOARD

Journal of the American Society of Plastic Surgeons
Official Organ of the American Association of Plastic Surgeons
Official Organ of the American Society for Aesthetic Plastic Surgery, Inc.
Official Organ of the American Society of Maxillofacial Surgeons

EDITORS

Editor

Rod J. Rohrich, M.D.
Department of Plastic Surgery
University of Texas Southwestern Medical Center
5323 Harry Hines Boulevard, HX1.636
Dallas, Texas 75390-8820
rjreditor_prs@plasticsurgery.org

Co-Editor

James M. Stuzin, M.D.
Suite 100
3225 Aviation Avenue
Coconut Grove, Fla. 33133

Review Editor

Jack A. Friedland, M.D.
101 E. Coronado Road
Phoenix, Ariz. 85004-1512

Advertising Editor

Mary H. McGrath, M.D.
Suite 520
1635 Divisadero
San Francisco, Calif. 94115

Editor Emeritus

Robert M. Goldwyn, M.D.
Brookline, Mass.

ASSOCIATE EDITORS

Scott Bartlett, Philadelphia, Pa.
Kevin C. Chung, Ann Arbor, Mich.
Howard M. Clarke, Toronto, Ontario
Mark A. Codner, Atlanta, Ga.
Gregory R. D. Evans, Orange, Calif.
Arun Gosain, Milwaukee, Wis.
Ronald P. Gruber, Oakland, Calif.
David A. Hidalgo, New York, N.Y.
David Knize, Englewood, Colo.
William Kuzon, Jr., Ann Arbor, Mich.
Michael T. Longaker, Stanford, Calif.
Thomas A. Mustoe, Chicago, Ill.
David T. Netscher, Houston, Texas
Dennis P. Orgill, Boston, Mass.
Julian J. Pribaz, Boston, Mass.
Michael A. Sadove, Indianapolis, Ind.
Joseph M. Serletti, Philadelphia, Pa.
J. Grant Thomson, New Haven, Conn.
Charles Thorne, New York, N.Y.
Nicholas B. Vedder, Seattle, Wash.
Charles N. Verheyden, Temple, Texas
Norman Weinzweig, Chicago, Ill.
S. Anthony Wolfe, Miami, Fla.
Michael Yaremchuk, Boston, Mass.
Ronald M. Zuker, Toronto, Ontario

CONSULTING EDITORS

Virginia A. Clark, Sequim, Wash.
Cho Y. Pang, Toronto, Ontario
David B. Sarwer, Philadelphia, Pa.

EDITORIAL STAFF

Managing Editor

Daniel Sullivan
DS-prs@plasticsurgery.org

Staff Editor

Edward Tynan
ET-prs@plasticsurgery.org

Assistant to the Editor

Barbara Porter
barbara.porter@utsouthwestern.edu

Editorial Assistant/Graphics Designer

Angela Burch
AB-prs@plasticsurgery.org

the skin, and the patient's wishes, we may add some form of mastopexy. This is necessary in less than 10 percent of the patients. Our preference is to delay this additional step for at least 3 months, and we explain this possibility to the patient preoperatively. We have found that such a delay not only improves the aesthetic outcome but, more importantly, reduces the morbidity associated with simultaneous breast augmentation and mastopexy. In addition, most patients find the outcome from breast augmentation alone quite satisfactory and do not opt for mastopexy. Figure 2 shows a 34-year-old patient with moderate ptosis of 4 cm before and after a bi-plane, double-pocket approach without mastopexy.

Severe ptosis. In "severe" ptosis, the nipple is at or below the lower contour of the breast. We also consider ptosis to be "severe" when the lower contour of the skin brassiere is more than 4 cm below the submammary fold. Our general approach consists of a two-stage operation, with mastopexy as our initial procedure. Breast augmentation is performed after a waiting period of about 3 months, with either subglandular or subpectoral insertion of the prosthesis based on the thickness of the subcutaneous tissue as discussed above.

The type of implant selected, the sites of incisions, and the form of mastopexy chosen (Peled-Benelli, Wise pattern, vertical, or other approaches) depend on the surgeon's preference and personal experience. As a general rule, we prefer a vertical-type mastopexy with subpectoral implantation.

DOI: 10.1097/01.PRS.0000157602.60476.82

Fereydown Don Parsa, M.D.
Michael Brickman, M.D.
Alan A. Parsa, B.A.
Department of Surgery
University of Hawaii
John A. Burns School of Medicine
Honolulu, Hawaii

Correspondence to Dr. Parsa
Department of Surgery
University of Hawaii
1329 Lusitana Street, Suite 807
Honolulu, Hawaii 96813
jdparsa@yahoo.com

REFERENCES

1. Spear, S. Augmentation/mastopexy: "Surgeon, beware." *Plast. Reconstr. Surg.* 112: 905, 2003.
2. Regnault, P. Breast ptosis: Definition and treatment. *Clin. Plast. Surg.* 3: 193, 1976.

AN ORDINARY RULER AND THE LIMBERG FLAP

Sir:

We read with interest the article by Jovanovic and Colic¹ on the use of a specially designed ruler to draw a Limberg flap. This is an interesting technique, but it provides the surgeon with only a small number of options. In our practice we use an ordinary ruler and a simple calculation to draw a Limberg flap of any size.

A Limberg flap requires the drawing of a rhombus with internal angles of 60 and 120 degrees, which in itself consists of four right-angle triangles with internal angles of 30, 60, and 90 degrees (Fig. 1).

In this rhombus, the height (AC) and width (CD) are linked by a constant ratio that can be determined with trigonometry (Fig. 2). With this knowledge, a Limberg flap of any size can be marked out using a straight ruler and a calculator.

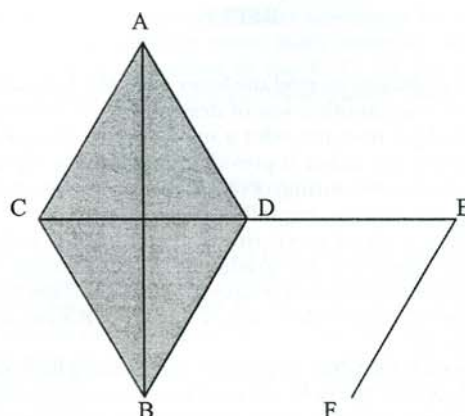


FIG. 1. Markings for a Limberg flap.

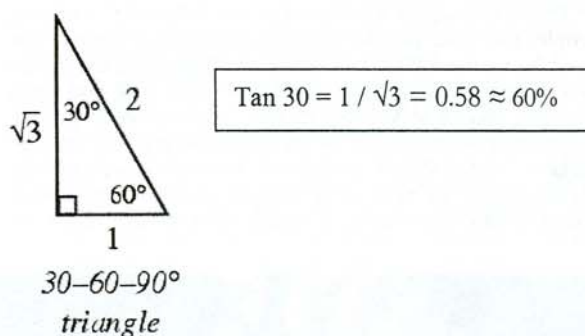


FIG. 2. Right-angle triangle.

Measure the height of the proposed rhombus and mark the half-way point. Next calculate 60 percent (or 0.58 to be exact) of this distance and draw a perpendicular line of this length centered on the half-way point.

Join the ends of these lines to mark the rhombus of tissue that will be excised during surgery (ABCD). To draw the flap that will rotate into this space, extend the midline by the same length to create line DE. Then measure the same distance in continuation with the border of the upper triangle to mark point F.

Finally, join up the two points E and F to complete marking of the flap. Using this technique, we have performed more than 100 Limberg flaps in 3 years with no episodes of flap necrosis or failure of rotation.

DOI: 10.1097/01.PRS.0000157603.90075.A6

W. Faux
D. M. Gold
Department of Surgery
North Hampshire Hospital
Hampshire, United Kingdom

Correspondence to Mr. Faux
Department of Surgery
North Hampshire Hospital
Aldermaston Road
Basingstoke, Hampshire RG24 9NA
United Kingdom

REFERENCE

1. Jovanovic, M. D., and Colic, M. M. Design of the Limberg flap by a specially designed ruler: A personal approach. *Plast. Reconstr. Surg.* 113: 653, 2004.

REPLY

Sir:

It was a pleasure to read the letter from Mr. Faux and Mr. Gold and learn another way of designing the Limberg flap. Our technique does not offer a small number of options to the surgeon, but rather it provides a method for rapid and highly precise measuring of all kinds of combinations of Limberg flap designs, regardless of size.¹

We have a set of seven rulers, including the universal one, with sides that are graduated in centimeters.¹ The ruler is used to design all lengths of Limberg flaps that are not found on other rulers (e.g., 2.7, 5.3, or 8.8 cm, and so on) (Fig. 1).

In the early phase of our practice with Limberg flaps, similar to Mr. Faux and Mr. Gold, we used mathematical calculations to design the Limberg flap.² However, we subsequently attempted to simplify the design and make the method faster and more precise through construction of our rulers.

The construction was aimed at the following: achieving simple, fast, and precise designs; sparing the surgeon the need for mathematical calculations; and avoiding the design of a rhomboid using height (AC) and width (CD) and using triangles placed within the rhomb. Application of the parameters upon drawing of the rhomboid on paper or on a flat surface is rather simple. In practice, however, drawing of the rhomboid on the skin to be excised, using any parameter found within the rhomb, is rather difficult and imprecise

because of the fact that tumors mostly protrude from the skin's surface, and it is impossible to draw over them. Thus, we used external contours of the rhomboid on the ruler to enable their placement over the tumor.¹

Our rulers are most helpful and their significance is high in designing the complex Limberg flaps in the technique termed by us "mini flaps for maxi defect," which necessitated high precision.¹ Using our technique, we have designed several hundred Limberg flaps of all kinds, combinations, and sizes without any limitations and with 100 percent precision.

DOI: 10.1097/01.PRS.0000157603.90075.A6

Milan D. Jovanovic, M.D., M.Sc.
Miodrag M. Colic, M.D., Ph.D.
Department of Plastic and Reconstructive Surgery
Institute for Burns
Clinical Centre of Serbia
Belgrade, Serbia and Montenegro

Correspondence to Dr. Jovanovic
Department of Plastic and Reconstructive Surgery
Institute for Burns
Clinical Centre of Serbia
Zvezanska
9 11 000 Belgrade, Serbia and Montenegro
aes.surg@eunet.yu

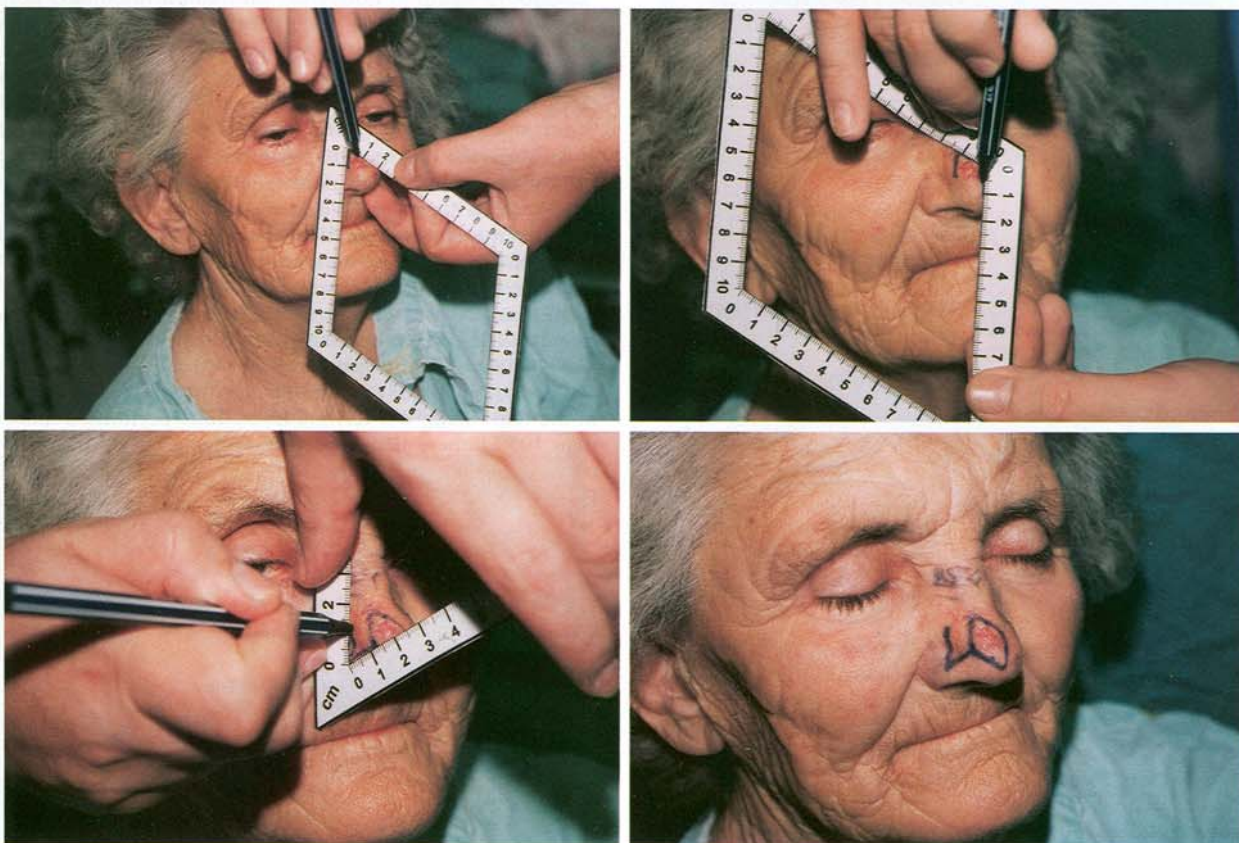

FIG. 1. (Above, left) Setting the ruler in the location of pathologic changes by orienting the ruler to the lines of maximum extension and designing two side rhomboid lengths of 1.2 cm set in position at 60-degree angles. (Above, right) Designing sides of rhomboid set in position at 120-degree angles. (Below, left) Designing the location of the Limberg flap. (Below, right) Designed Limberg flap.

REFERENCES

1. Jovanovic, M., and Colic, M. Design of the Limberg flap by a specially designed ruler: A personal approach. *Plast. Reconstr. Surg.* 113: 653, 2004.
2. Limberg, A.A. *Mathematical Principles of Local Plastic Procedures on the Surface of the Human Body*. Leningrad: Medgiz, 1946.

PERIAREOLAR MAMMAPLASTY
PATIENTS' PERSPECTIVE

Sir:

We would like to congratulate Fayman et al. for their attempt to objectively evaluate the patients' perspective regarding periareolar mammaplasty.¹ However, we also would like to critique two important points related to their article. First, the authors overlooked some important points in the historical development of this technique and failed to give credit to some important contributors to periareolar mammaplasty in their evaluation. Therefore, it is important to note the onset of the popularization of this technique. Rossell and Stark,² in 1973, presented the circumareolar approach for the correction of breast hypertrophy and ptosis. A similar approach was utilized by Bartels et al.³ in 1976, using a donut-shaped excision of skin to reduce the breast skin brassiere. In 1990, Erol and Spira⁴ opened a new era using the "rotation-invasion procedure," a mastopexy technique for mild to moderate ptosis with no skin excision. Thereafter, many contributions appeared in the literature, as stated by the authors. In addition, we do not agree with the authors' statement that "the technique results in rounder and less projecting breasts." It has previously been shown that the rotation-invasion procedure gives a more conical shape to the breast and increases its projection in the ideal patient, who is a young woman with small and mildly to moderately ptotic breasts.^{4,5} However, it must also be emphasized that women with markedly ptotic breasts and severe loss of skin elasticity are not good candidates for this procedure.

DOI: 10.1097/01.PRS.0000157607.09572.E8

Hakan Gundogan, M.D.
O. Onur Erol, M.D.
ONEP Plastic Surgery Science Institute
Levent, Istanbul, Turkey

Correspondence to Dr. Erol
ONEP Plastic Surgery Science Institute
Manolyali sok. No. 33
80620 Levent, Istanbul, Turkey
onep@onep.com.tr

REFERENCES

1. Fayman, M. S., Potgieter, E., and Becker, P. J. Outcome study: Periareolar mammaplasty patients' perspective. *Plast. Reconstr. Surg.* 111: 676, 2003.
2. Rossell, E., and Stark, R. B. Circumareolar mastopexy. Presented at the American Society of Plastic and Reconstructive Surgeons Convention, October 23, 1973, Hollywood, Fla.
3. Bartels, R. J., Strickland, D. M., and Douglas, W. M. A new mastopexy operation for mild or moderate breast ptosis. *Plast. Reconstr. Surg.* 57: 687, 1976.
4. Erol, O. O., and Spira, M. A mastopexy technique for mild to moderate ptosis. *Plast. Reconstr. Surg.* 65: 603, 1980.

5. Erol, O. O. Erol's periareolar mastopexy for different types of mammary ptosis: Mild, moderate, severe, hypoplastic. Presented at the RAPS III International Symposium, São Paulo, Brazil, March 14-15, 1992.

REPLY

Sir:

I thank Drs. Gundogan and Erol for their interest in our article, entitled "Outcome Study: Periareolar Mammaplasty Patients' Perspective,"¹ and for their valuable comments. I wish to make the following remarks relating to their criticism.

We acknowledge the contribution made by Dr. Bartels et al.,² Dr. Erol et al.,³ and many others to breast aesthetic surgery. The focus of our study was patients' perception of the result rather than technical details of the periareolar mammaplasty, with particular reference to the technique utilized by the authors, which is different from the techniques described by the above-mentioned authors. This was the reason for not mentioning the above contributors.

With regard to the criticism leveled at the statement made about rounder and less projecting breasts using the periareolar technique compared with the vertical mammaplasty technique, please note that this statement was not the authors' conclusion, rather it was a summary of criticism expressed by previous writers against the periareolar mammaplasty. This statement was challenged by our study and found to be not significant in the eyes of prospective and past patients.

DOI: 10.1097/01.PRS.0000157608.41231.C9

M. Fayman, M.D.
Rosebank Clinic
Suite 17, Rosebank Clinic
14 Sturdee Avenue
Rosebank 2196
P.O. Box 1708
Parklands, 2121 Johannesburg, South Africa
info@doctorfayman.co.za

REFERENCES

1. Fayman, M. S., Potgieter, E., and Becker, P. J. Outcome study: Periareolar mammaplasty patients' perspective. *Plast. Reconstr. Surg.* 111: 676, 2003.
2. Bartels, R. J., Strickland, D. M., and Douglas, W. M. A new mastopexy operation for mild or moderate breast ptosis. *Plast. Reconstr. Surg.* 57: 687, 1976.
3. Erol, O. O., and Spira, M. A mastopexy technique for mild to moderate ptosis. *Plast. Reconstr. Surg.* 65: 603, 1980.

CORRECTION OF POSTBURN
BREAST DEFORMITY

Sir:

In response to Dr. O. Onur Erol's letter entitled "Correction of Postburn Breast Deformity" (*Plast. Reconstr. Surg.* 115: 358, 2005), we would first like to acknowledge the excellent results obtained by Drs. Erol and Spira in their surgical treatment of six patients with breast deformity secondary to burns.¹ We recognize that the areola transposition technique used in our postburn case² has similarities to that utilized by Erol and Spira, but there are also a number of differences.

First, because the burn scar contracture resulted in two indistinct inframammary folds, a significant part of the operation per-